

Original article:

Assesment of cytomorphological features of colloid Goitre so as to improve the diagnostic accuracy

¹Dr. Ritu Agrawal, ²Dr. V. B. Shivkumar* , ³Dr. Sushma Nagale , ⁴Dr. Nitin Gangane

¹Assistant Professor, Department of Pathology, MGIMS, Sewagram

²Professor, Department of Pathology, MGIMS, Sewagram

³Private practitioner

⁴Professor And Head, Department of Pathology, MGIMS, Sewagram

Corresponding author*

Abstract:

Introduction: Fine needle aspiration cytology is the first line investigation for assessment of thyroid nodules. Amongst the thyroid nodules routinely encountered in clinical practice, goiter is the commonest. The colloid goiter has a variable cytomorphological features and therefore leads to many misdiagnosis.

Aim and objective: To study the detailed cytomorphological features of colloid goiter in histologically proven cases, so as to reduce the discrepancy in cytological diagnosis.

Material and Method: The study was done over a period of six months at Mahatma Gandhi Institute of Medical Sciences, Sevagram. A total of 100 histologically diagnosed cases of colloid goiter were taken and their detailed cytomorphological features were studied.

Result: On detailed assessment of cytomorphological features of colloid goiter, it was found that they have a variable morphology. The cellularity of smears ranged from low cellular to highly cellular with various epithelial arrangements of follicular cells like loose aggregates and lying singly, honeycomb flat sheets with aggregates, follicular arrangement, syncytial clusters and occasional papillary clusters. 87% of cases showed presence of thin colloid while the 13% cases had both thin and thick colloid. The important finding was presence of Hurtle cells in 14% cases and lymphocytes in the background of 18% of the cases. The intranuclear cytoplasmic inclusion was noted in 2 cases leading to the discordant diagnosis of papillary carcinoma thyroid.

Conclusion: Despite the fact that, fine needle aspiration cytology provides substantial diagnostic accuracy, there remains a definite low incidence of discordant diagnosis of colloid goiter; the vigilant look on all cellular and cytomorphological feature of colloid goiter can further avoid the discrepancy.

Key Words: FNAC, Colloid goiter, cytomorphology.

INTRODUCTION:

The thyroid is unique amongst endocrine glands as it is largest and due to its superficial location, it is only one endocrine gland that is amenable to physical examination and biopsy. The most common presentation is presence of palpable thyroid nodule.

In India the prevalence of a palpable thyroid nodule is about 12.2%⁽¹⁾. The colloid goiter is most common cause of thyroid nodule. Goiter results from a deficiency of thyroid hormone synthesis induced by iodine deficiency leading to increasing in TSH secretion, which results initially in tall follicular

epithelium and later on in follicular atrophy with massive storage of colloid leading to colloid goiter. Thus colloid goiter is most common lesion encountered during clinical practice in a patient with thyroid mass.

Fine needle aspiration cytology remains the first choice for the initial investigation and diagnosis of both superficial and deep lesions of the thyroid. FNAC has many advantages like it's relatively painless, cheap and produces speedy results. Although FNAC has low incidence of false positive or negative results, while diagnosing colloid goiter, there are still scope to improve the diagnostic accuracy and avoid discrepancy in the diagnosis on cytology.

The study was done with the objective of assessing the detailed cytomorphological features of colloid goiter and to evaluate the discrepancy. The study aims in further improving the diagnostic accuracy of cytology.

MATERIALS AND METHOD:

The study was carried out in the cytology section of Department of Pathology, Mahatma Gandhi Institute of Medical Sciences, Sevagram. A total 100 cases of histologically diagnosed colloid goiter on which fine needle aspiration cytology was done were selected.

This was a laboratory based observational study. Ethical clearance was obtained from the Institutional ethical committee. The relevant case history with

demographic information and clinical details were obtained.

In each case, all the slides were retrieved from the cytology as well as histology section of the department of Pathology. Cytology slides were reviewed for detailed cytomorphological features.

The slides were stained with May-Grunwald-Giemsa and Papanicolaou stain.

OBSERVATION AND RESULTS

Amongst the 100 histologically diagnosed cases of colloid goiter studied, the youngest patient was 14 years and oldest was 75 years old. Median age was 38years. The maximum number of cases (35%) was in the fourth decade. In this study, there was female preponderance with 85% being female.

Detailed cytomorphological features in all the 100 cases which included- cellularity, arrangement of epithelial component, characteristic of cytoplasm, nuclear features, characteristic of colloid, and the background were noted.

CELLULARITY:

This was graded as low, moderate and high. The majority of cases 61% had low cellularity, 30% had moderate cellularity while only 9% had high cellularity.

EPITHELIAL ARRANGEMENT OF FOLLICULAR CELLS (Figure 1)

The predominant arrangement of follicular cells differed according to the cellularity of smears as shown in table 1.

Table 1: Epithelial Arrangement of Follicular Cells

LOW CELLULAR SMEARS			MODERATE CELLULAR SMEARS			HIGH CELLULAR SMEARS		
Epithelial arrangement	No. of cases	% cases	Epithelial arrangement	No. of cases	% cases	Epithelial arrangement	No. of cases	% cases
Aggregates with dispersed singly	35	57.37%	Honeycomb sheets with aggregates & dispersed singly	15	50%	Honeycomb sheets with aggregates	4	44.44%
Honeycomb with aggregates & dispersed singly	12	19.67%	Follicular	5	16.67%	Follicular	2	22.22%
Syncytial with aggregates	5	8.19%	Papillary	3	10%	Syncytial	2	22.22%
Aggregates	04	6.56%	Syncytial	4	13.33%	Spherular	1	11.11%
Follicular	04	6.56%	Spherular	3	10.0%			
Total	61	100	Total	30	100	Total	9	100

It was observed that in low cellular smears, most of the follicular cells were found in aggregates and dispersed singly, whereas in smears with moderate and high cellularity, the follicular cells were found in honeycomb sheets along with aggregates of follicular cells.

CYTOPLASM

The cytoplasm was basically characterized as feathery (45%) (Fig2-c), pale (10%), clear (06%) or unremarkable (39%).

Cytoplasm was found metaplastic (Hurtle cells) in 14% of cases. Other features were the presence of paravacuolar granules (Fig 2-f) in 11% cases and fire flare appearance (Fig 2-e) in 6% cases.

NUCLEAR FEATURES:

It was found that in most of the cases of colloid goiter (64%) there was presence of bare nuclei. While bare nuclei along with anisonucleosis were present in 18% of cases and anisonucleosis alone was present in 10% of cases. Nucleoli and intranuclear inclusions (Fig 2-d) were found in 6% and 2%cases respectively.

COLLOID:

The amount of colloid ranged from minimal to moderate and extensive. 50% of cases showed extensive colloid, 37% showed a moderate amount of colloid while 13% had minimal colloid.

The smears were found to have either thick or thin colloid. In the majority of cases, 87% had thin colloid (Fig2-a). While 13% were found to have both thick (Fig2-b) and thin colloid.

BACKGROUND:

Table 2: Background component

CELLULAR BACKGROUND		NON CELLULAR BACKGROUND	
BACKGROUND	NO OF CASES	BACKGROUND	NO OF CASES
Cyst macrophages	51	Hemorrhage	66
Lymphoid cell	18	Hemorrhagic with cyst macrophages	18
Hemosiderin laden macrophages	06	Hemorrhagic with lymphoid cells	07
Giant cells	05	Calcified debris	02
Histiocytes	01	Fibrous strands	01
Total	81	Others	06

Background of smears of colloid goiter as shown in table 2 constitute of cellular elements like lymphoid cells, histiocytes, giant cells, cyst macrophages and hemosiderin-laden macrophages. The noncellular material like hemorrhage, fibrous strands, and calcified debris were also found in the background.

It was found that 81% case had the cellular background.

CYTOLOGY- HISTOLOGY CORRELATION

Amongst the 100 histologically diagnosed cases of colloid goiter, a cytological correlation was obtained in 95 cases, whereas 05 cases differed in cytological diagnosis. Amongst the discordant cases, 2 cases were diagnosed as a follicular neoplasm of the thyroid, 2 cases as papillary carcinoma thyroid and 1 case as Hashimoto's thyroiditis.

DISCUSSION

The colloid goiter is most common thyroid lesion encountered in clinical practice. The FNAC smears of colloid goiter have variable cellular and morphological features which sometimes lead to the false positive diagnosis of thyroid malignancy. In order to avoid such discrepancy, it is important to analyze and assess each and every cellular and cytomorphological feature of colloid goiter.

The FNA smears of colloid goiter are graded according to the cellularity as 1+, 2+, and 3+. Majority of smears of colloid goiter usually have low (1+) cellularity^(2, 3); which is in consistent with the

findings of the present study as 61 out of 100 cases had low cellularity.

The predominant epithelial arrangement in the low cellular smears of colloid goiter is mainly in the form of loose aggregates and lying singly^(2, 4, 5). Other less frequent epithelial patterns are honeycomb flat sheets with aggregates, follicular arrangement, syncytial clusters and occasionally papillary clusters can be seen⁽³⁾. In the present study, it was observed that 57% of low cellular smears had cells lying singly as well as in loose aggregates.

The cytoplasmic characteristic of the follicular cells has been described by several authors. According to

the study done by Kini et al the follicular cell cytoplasm has wispy texture and the cell borders are poorly defined⁽⁵⁾. The cytoplasm of the follicular cells was described as feathery by Layfield et al⁽⁶⁾ whereas, Perter M Crockford et al⁽⁷⁾ in their study found the presence of vacuolated cytoplasm in the smear of colloid goiter with no clearly defined borders. In the present study, a majority of the cases (45 cases) the cytoplasm was predominantly feathery. In 39 cases the cytoplasm was unremarkable.

In the present study, 14% of cases showed the presence of Hurtle cells. Hurtle cells may be found in a wide variety of conditions affecting the thyroid gland; they are not specific to any particular pathology⁽⁸⁾. They are commonly found in older individuals, those who have undergone thyroid irradiation, and patients with long-standing nodular goiters, Graves' disease, and Chronic lymphocytic thyroiditis. Hurtle cells are seen in 5-15% of cases of colloid goiter^(3,9).

Another finding observed in the current study was the presence of paravacuolar granules which were seen in 11% of cases.

Paravacuolar granules were earlier thought to be associated with the secretory function of the cells and possibility of a cytological diagnosis of hyperthyroidism based on the rich occurrence of these granules⁽¹⁰⁾. Later on, after doing histochemical and ultrastructural studies, these granules were classified as pigments which are predominantly composed of hemosiderin and lipofuscin. These granules are not associated with hyperactivity, rather they merely reflect the erythro- phagocytic capability of thyroid epithelial cells under hemorrhagic conditions⁽¹¹⁾

Another morphological feature observed was the presence of marginal vacuoles in 6% of cases.

Soderstrom et al in 1972 were the first to discuss marginal vacuoles in the cytoplasm of follicular cells in smears from toxic goiters⁽¹²⁾. Marginal vacuoles (MVs) have been described as irregular cytoplasmic vacuoles measuring 1-7 μm in diameter, deeply eosinophilic in the periphery with a largely unstained central area on May-Grünwald-Giemsa (MGG) stained smears. They tend to gather peripherally in a group of follicular epithelium and hence are called marginal vacuoles. The term fire flare has also been used because of the resemblance of MVs to a rising or spreading fire⁽¹³⁾. Das et al⁽²⁾ found the presence of these granules in 5.2% of cases of colloid goiter, which are similar to our study(6%).

Intranuclear inclusions, when present, are suggestive of the lesion with high chances of malignancy⁽¹⁴⁾. However, it can be seen occasionally in cases of colloid goiter also, leading to the misdiagnosis of papillary carcinoma thyroid⁽¹⁵⁾

Intranuclear inclusions were seen in 2 cases in the present study and both the cases on fine needle aspiration cytology were diagnosed as suspect papillary carcinoma on the basis of this finding.

The important clue towards a diagnosis of colloid goiter is the presence of abundant colloid in the background. The finding of abundant colloid in the majority of cases of colloid goiter are corroborated by the findings of several authors^(3, 16-18) All of them observed that a definitive diagnosis of colloid goiter can be made in the smear which contains abundant colloid along with follicular cells. Thin colloid stains light blue with Giemsa stain and light green with the Pap stain and watery colloid has a tendency to crack, thick or dense colloid stains dark blue with Pap and dark purple with Giemsa stain⁽¹⁹⁾

In the present study, an extensive amount of colloid was observed in 50% of cases and 87% of cases had thin colloid.

The smears of colloid goiter had a cellular background either alone or in combination with the noncellular material. Cellular background consisted of cyst macrophages, hemosiderin laden macrophages, lymphocytes, giant cells, and histiocytes.

The background of colloid goiter may contain inflammatory cells like lymphocytes, plasma cells and giant cells⁽²⁾. Hemosiderin laden macrophages are usually found whenever there is evidence of old bleeding^(3, 17).

In the present study also lymphocytes were present in 18% cases. Hemosiderin laden macrophages were present in 6 cases. Giant cells were present in 5 cases and in a lone case histiocyte was present.

The secondary changes in colloid goiter are quite common and include hemorrhage, cyst formation, granulation tissue, fibrosis and calcification⁽²⁰⁾. In our study, we found hemorrhage in the majority of cases. While calcified debris was seen in 2 cases and the fibrous strand was seen in 1 case only.

After retrospectively reviewing the cytological smears of the histologically proven case of colloid goiter, it was found that 5 discordant cytological diagnoses were given.

In one of the case, there was a scant amount of colloid with moderate cellularity showing follicular cells along with lymphocytes in one of the field. Hurtle cells were also seen. So the discordant diagnosis of Hashimoto's thyroiditis was given on cytology smears. On histopathological examination of the surgical specimen, it was seen that it was the case of colloid goiter with focal areas of lymphocytic infiltration and Hurtle cell metaplasia of the follicular

cells. Such type of discordant diagnosis is common in cytology and can be avoided by repeat sampling from different sites^(21, 22).

Another discordant diagnosis observed in the 2 cases of the present study was of follicular neoplasm on cytology, which was later on found to be the cases of colloid goiter on histology. Such discordant diagnosis of follicular neoplasm is because the cytological appearance of colloid goiter overlap with the follicular adenoma, especially if the micro-follicular focus in the nodular goiter is selectively sampled; the smear shows repetitive patterns of microfollicles with no colloid, distinction from follicular neoplasm may be impossible⁽²³⁾. This is the most important cause of discordant diagnosis of follicular neoplasm in the present study also. This could be rectified if the aspiration is done from more than one area; it may show microfollicles, abundant colloid and degenerative changes recognizable as colloid goiter.

In the present study, in 2 cases a diagnosis of papillary carcinoma was given on cytology. In the first case abundant colloid was aspirated on the first aspiration and then on repeat aspiration, moderate cellularity was seen with follicular cell nuclei showing prominent intranuclear cytoplasmic inclusion. In another case, occasional papillary fragments were also seen. Considering all these and more particularly prominent intranuclear cytoplasmic inclusion a diagnosis of papillary carcinoma was given in both the cases on cytology. However, studies emphasize that all major and minor criteria should be incorporated for diagnosis of papillary carcinoma thyroid on FNA smears⁽²⁴⁾.

CONCLUSION:

Fine needle aspiration cytology provides substantial diagnostic accuracy with a low incidence of false positive results for the diagnosis of colloid goiter.

However, the accuracy can further be improved by doing multiple passes from different sites, also, emphasis to be given to each and every variable of cytomorphology of colloid goiter while providing diagnosis on cytology.

REFERENCES:

1. Unnikrishnan AG, Kalra S, Baruah M, Nair G, Nair V, Bantwal G, et al. Endocrine Society of India management guidelines for patients with thyroid nodules: A position statement. *Indian J Endocrinol Metab.* 2011 Jan;15(1):2-8.
2. Das DK, Khanna CM, Tripathi RP, Pant CS, Mandal AK, Chandra S, et al. Solitary nodular goiter. Review of cytomorphologic features in 441 cases. *Acta Cytol.* 1999 Jul-Aug;43(4):563-74.
3. Jayaram G. Fine needle aspiration cytologic study of the solitary thyroid nodule. Profile of 308 cases with histologic correlation. *Acta Cytol.* 1985 Nov-Dec;29(6):967-73.
4. Ravinsky E, Safneck JR. Fine needle aspirates of follicular lesions of the thyroid gland. The intermediate-type smear. *Acta Cytol.* 1990 Nov-Dec;34(6):813-20.
5. Kini SR, Miller JM, Hamburger JI, Smith-Purslow MJ. Cytopathology of follicular lesions of the thyroid gland. *Diagn Cytopathol.* 1985 Apr-Jun;1(2):123-32.
6. Layfield LJ, Wax T, Jones C. Cytologic distinction of goiterous nodules from morphologically normal thyroid: analyses of cytomorphologic features. *Cancer.* 2003 Aug 25;99(4):217-22.
7. Crockford PM, Bain GO. Fine-needle aspiration biopsy of the thyroid. *Can Med Assoc J.* 1974 May 4;110(9):1029-32.
8. Baloch ZW, LiVolsi VA, Asa SL, Rosai J, Merino MJ, Randolph G, et al. Diagnostic terminology and morphologic criteria for cytologic diagnosis of thyroid lesions: a synopsis of the National Cancer Institute Thyroid Fine-Needle Aspiration State of the Science Conference. *Diagn Cytopathol.* 2008 Jun;36(6):425-37.
9. Das DK. Marginal vacuoles (fire-flare appearance) in fine needle aspiration smears of thyroid lesions: does it represent diffusing out of thyroid hormones at the base of follicular cells? *Diagn Cytopathol.* 2006 Apr;34(4):277-83.
10. Soderstrom N. Puncture of goiters for aspiration biopsy. *Acta Med Scand.* 1952;144(3):237-44.
11. Sidawy MK, Costa M. The significance of paravacuolar granules of the thyroid. A histologic, cytologic and ultrastructural study. *Acta Cytol.* 1989 Nov-Dec;33(6):929-33.
12. Soderstrom N, Nilsson G. Cytologic diagnosis of thyrotoxicosis. *Acta Med Scand.* 1979;205(4):263-5.
13. Gupta A, Singhal M, Kalhan S, Singhal O, Kaur V. Cytomorphologic significance of marginal vacuoles in diffuse thyroid enlargements. *J Cytol.* 2013 Apr;30(2):125-9.
14. Arena S, Latina A, Stornello M, Saraceno G, Benvenga S. Intranuclear cytoplasmic inclusions in cytologically suspicious or malignant thyroid nodules: identification and correlation with echogenicity and size of the nodules. *Endocrine.* 2014 May;46(1):114-22.
15. Pandey Pinki DA, Mahajan Nanak C. Fine-needle aspiration of the thyroid: A cytohistologic correlation with critical evaluation of discordant cases. *Thyroid Res Pract.* 2012; 9(2):32-9
16. Mehrotra A, Agarwal PK, Chandra T. Cytopathology and AgNOR counts in fine-needle aspiration cytology smears of thyroid lesions. *Diagn Cytopathol.* 1998 Oct;19(4):238-43.
17. Nassar A, Gupta P, LiVolsi VA, Baloch Z. Histiocytic aggregates in benign nodular goiters mimicking cytologic features of papillary thyroid carcinoma (PTC). *Diagn Cytopathol.* 2003 Nov;29(5):243-5.
18. Mathur SR, Kapila K, Verma K. Role of fine needle aspiration cytology in the diagnosis of goiter. *Indian J Pathol Microbiol.* 2005 Apr;48(2):166-9.

19. Biscotti CV, Hollow JA, Toddy SM, Easley KA. ThinPrep versus conventional smear cytologic preparations in the analysis of thyroid fine-needle aspiration specimens. *Am J Clin Pathol.* 1995 Aug;104(2):150-3.
20. Merino MJ SMK. The thyroid gland. In: Silverberg SG, editor *Principles and Practice of Surgical Pathology and Cytopathology* New York:Churchill Livingstone. 1997:2677.
21. Bakhos R, Selvaggi SM, DeJong S, Gordon DL, Pitale SU, Herrmann M, et al. Fine-needle aspiration of the thyroid: rate and causes of cytohistopathologic discordance. *Diagn Cytopathol.* 2000 Oct;23(4):233-7.
22. Jayram G. Introduction, general and technical consideration. *Gita jayram Atlas and text of thyroid cyology.* New Delhi: Arya Publication; 2006.
23. Droese M. *Cytological Aspiration Biopsy of Thyroid Gland.* 1980 ed: Stuttgart, FK Schattauer Verlag; 1980. p. 62-3,220-1.
24. Fiorella RM, Isley W, Miller LK, Kragel PJ. Multinodular goiter of the thyroid mimicking malignancy: diagnostic pitfalls in fine-needle aspiration biopsy. *Diagn Cytopathol.* 1993;9(3):351-5.

Figure—1 : Epithelial arrangement of Follicular cells.

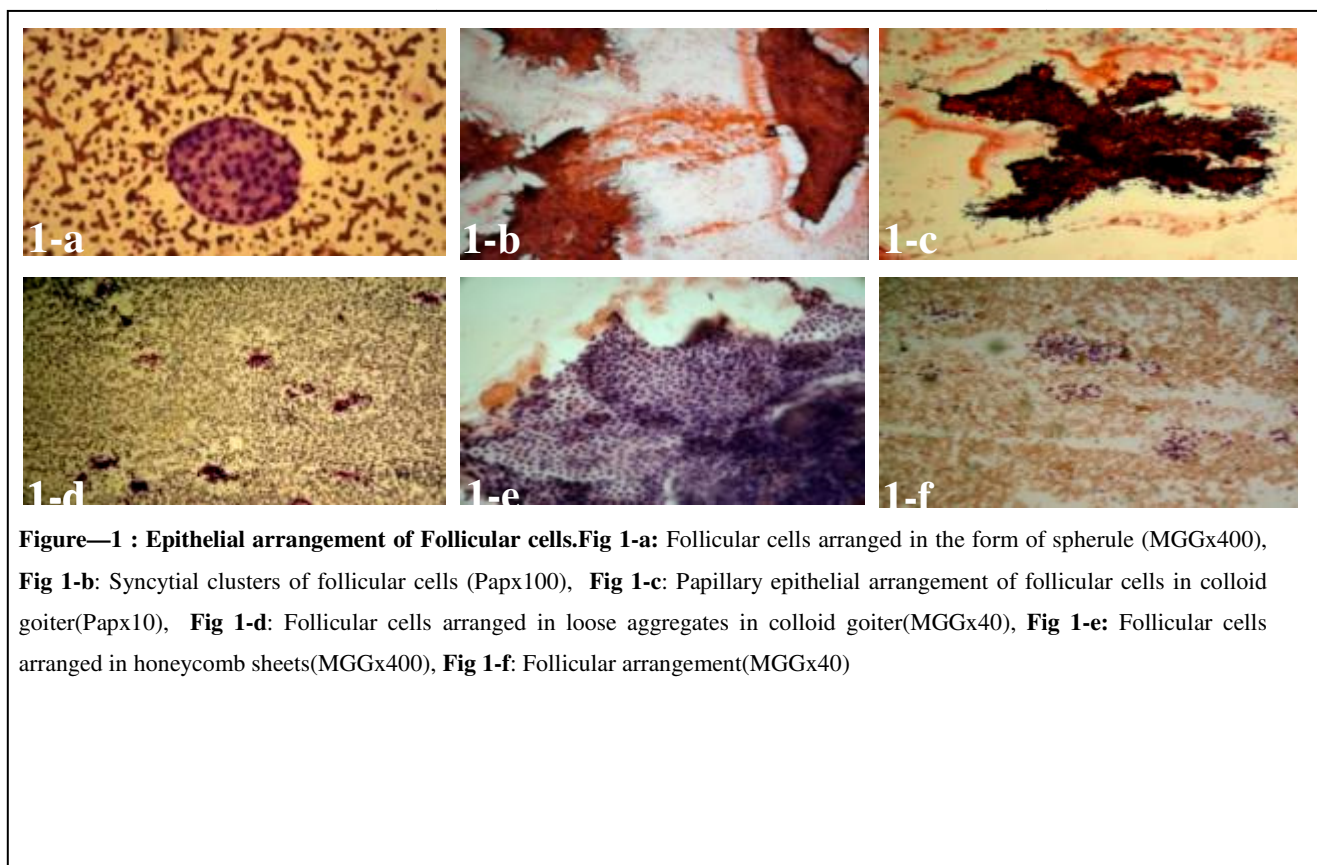


Figure-2: Various cytological features:

